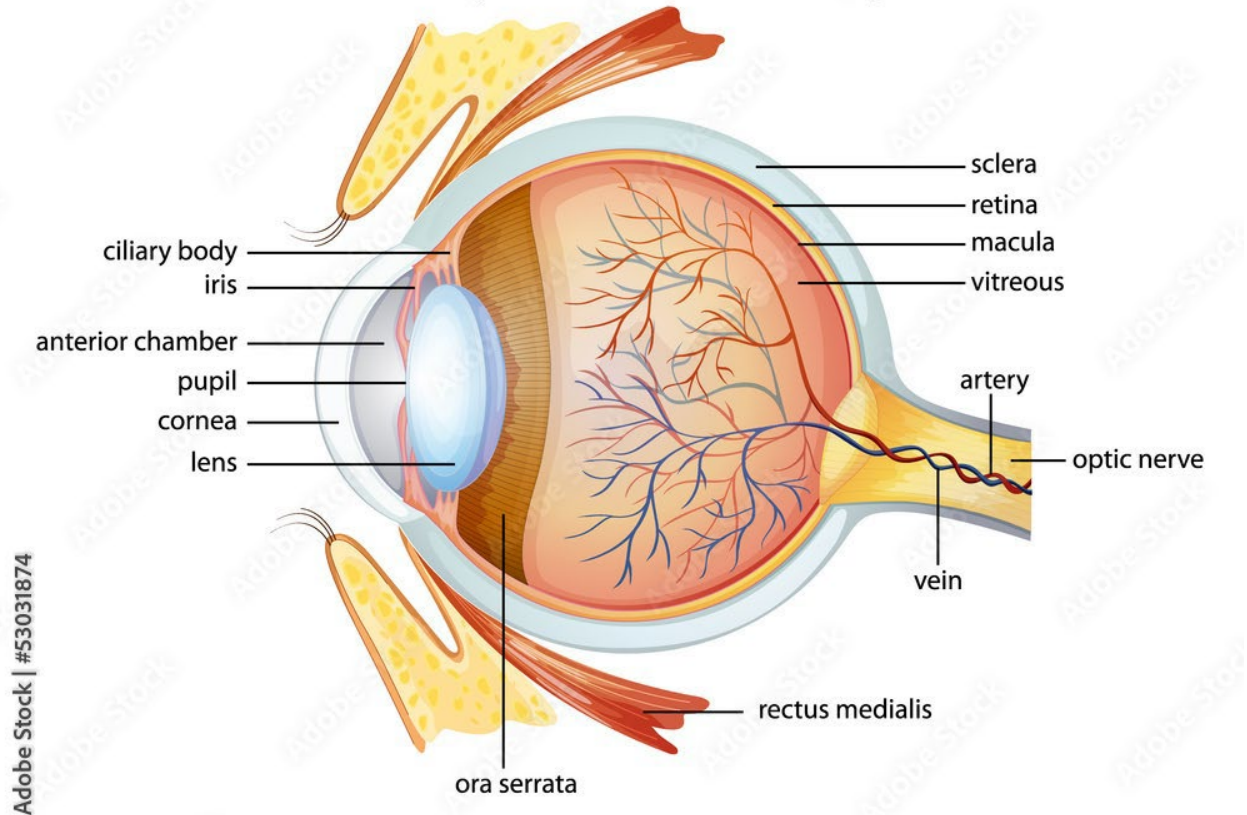


Anatomy of the Human Eye



Laser eye surgery:

The three laser eye surgeries proposed (YAG Capsulotomy, Selective Laser Trabeculoplasty, and Laser Peripheral Iridotomy) are highly specialized surgeries used to target very precise anatomy inside the eye. These laser surgeries can be performed in a clinic setting and use a laser attached to a device called a “slit lamp”, a low powered microscope with a high-intensity light that cuts tissue. Both optometrists and ophthalmologists are skilled at using slit lamps to examine patients. Because these laser surgeries are performed in the office using a modified slit lamp, optometrists extrapolate this to mean laser eye surgery is low risk. Each surgery uses **micro explosions** to cut specific areas of the eye, and each carries the risk of serious complications. Lasers are surgical instruments that cut as deeply and sharply as any scalpel and these surgeries are considered invasive even if they generally do not result in bleeding of tissues.



Representative photo of patient receiving laser eye surgery at a slit lamp

Nd:YAG Laser Posterior Capsulotomy (“YAG Capsulotomy”). CPT 66821.

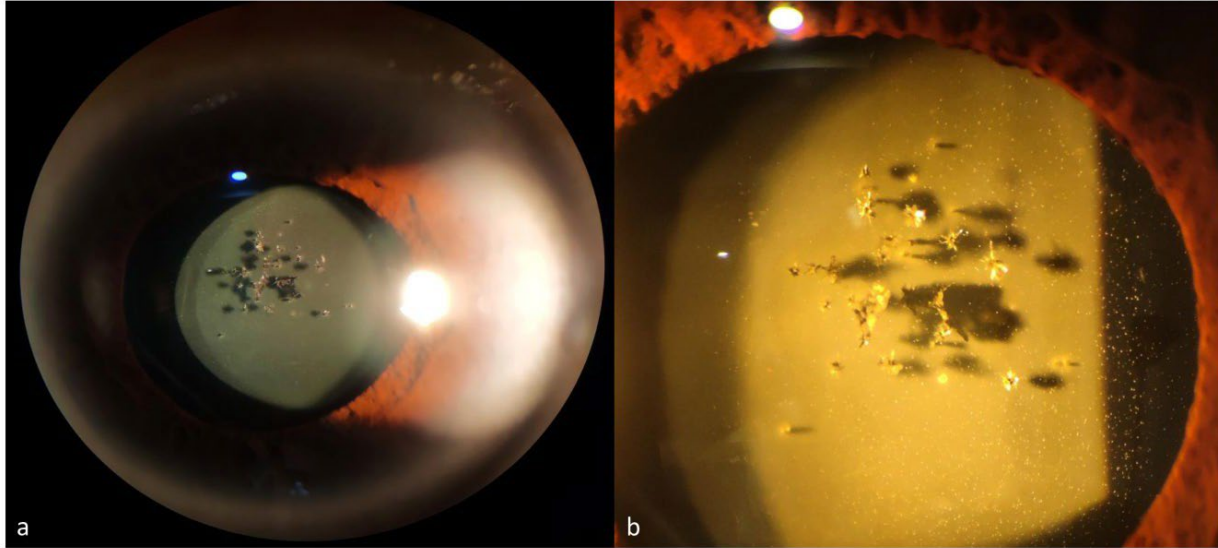
Approximately one-third of patients will benefit from this laser treatment in the years following cataract surgery. An opacified membrane (“posterior capsule opacification”) forms behind the intraocular implant (IOL) that is placed at the time of cataract surgery and causes blurry vision, often like what was experienced with a cataract. The laser is used to make an opening in the cloudy capsule behind the IOL. This allows light to pass through again for clear vision. Of note, this membrane is only 3 microns thick (the width a strand on a spider’s web) and adherent to the intraocular implant due to contraction after cataract surgery.

Complications include damage to the IOL from the laser (pitting), elevated intraocular pressure, retinal swelling, retinal holes, retinal detachment, corneal abrasion or corneal edema. If the IOL is damaged or, in the case of a retinal complication, the person could require an additional and more complex surgery in an operating room. If this laser needs to be performed, it is only needed **once** in a patient’s lifetime. Depending on patient and surgeon preference, it can be performed on both eyes the same day, and it is almost never needed on an urgent basis.

Reference: <https://www.aao.org/education/current-insight/ndyag-laser-posterior-capsulotomy-3>

A cross section of an eye where the YAG laser is aimed into the eye behind the artificial lens implant to cut through the capsule and create an opening.

[Photo from <https://www.eyedoctorophthalmologistnyc.com/treatment/yag-capsulotomycomplications/>]

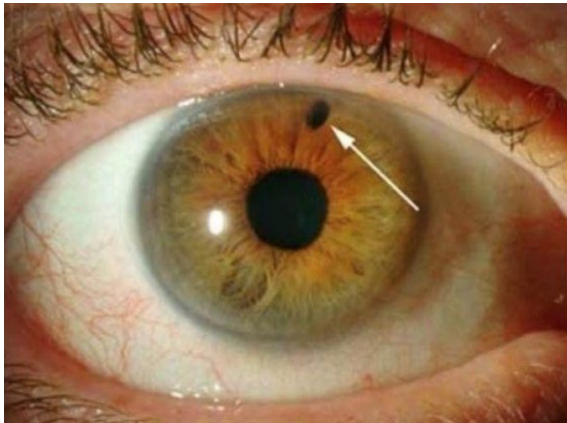


Laser “pitting” on intraocular lens surface causing visual disturbance from scattered light. Photo from <https://www.mathewsopenaccess.com/full-text/iol-pitting-in-an-opacified-iol-post-nd-yag-capsulotomy>]

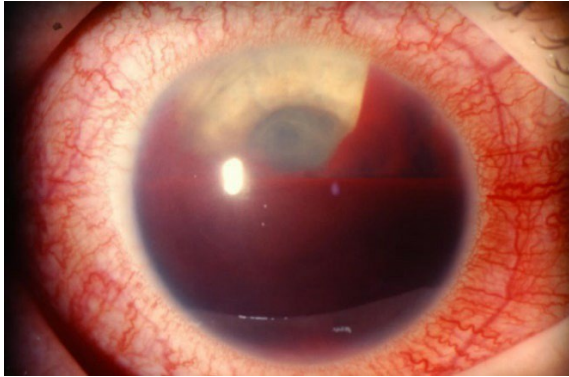
Laser Peripheral Iridotomy (“YAG Peripheral Iridotomy” or “LPI”). CPT 66761.

This surgery involves the creation of a tiny opening in the iris (the colored part of the eye) to improve the flow of aqueous fluid in the eye. It is done to treat specific types of glaucoma, but can also be indicated to treat “narrow” anatomy (also referred to as “anatomic narrow angles”) which can sometimes increase a patient’s risk for a very rare, but vision threatening type of glaucoma called angle closure glaucoma. Angle closure glaucoma is a true emergency, and this type of laser needs to be performed as soon as possible to reduce risk of vision loss. Performing an iridotomy for this condition can be **extremely challenging** due to patient discomfort and a poor view. Laser peripheral iridotomy has been a common treatment for anatomic narrow angles, but recent studies suggest a lower risk of progression to angle closure glaucoma than was previously believed. Therefore, **observation** is warranted in many cases (“ZAP” study, link below). In patients with clear indications for treatment, most ophthalmologists now tend toward performing cataract surgery which offers a cure for this condition. Since optometrists cannot perform cataract surgery, there is a risk of **unnecessary** Laser Peripheral Iridotomy surgeries by optometrists instead of referral for urgent cataract surgery.

Iridotomy surgery is performed at a laser mounted slit lamp. Complications include worsening eye pressure, inflammation, corneal abrasion, scarring of the pupil, bleeding in the eye, permanent visual disturbance (glare/haloes), cataract progression and retinal swelling or holes. Bleeding inside the eye with this type of laser is common because the iris has blood vessels that become very swollen when the eye is inflamed. Bleeding risk is even higher if a patient takes a blood thinner, and can be difficult to manage leading to dangerously high eye pressure and the need for surgery in an operating room to remove the blood and lower the pressure inside the eye. LPI surgery for anatomic narrow angles only needs to be performed **once** in a patient's life. Depending on patient and surgeon preference, LPI surgery for anatomic narrow angles, can be performed in both eyes on the same day and it is never needed on an emergency basis.



The arrow shows the location of the peripheral iridotomy – the full thickness permanent hole in the iris. [Photo from <https://www.synergyeye.com/investigation-yag-laser-pi.html>]



Blood in the anterior chamber of the eye, a potential complication from Laser Peripheral Iridotomy. [Photo from <https://healthjade.com/hyphema/>]

References: https://eyewiki.org/Laser_Peripheral_Iridotomy

<https://www.aao.org/eyenet/article/zap-light-and-salt>

Selective Laser Trabeculoplasty (“SLT”). CPT 65855

This surgery is used to treat glaucoma. The laser is applied to the drainage tissue in the eye (an anatomical location called the “angle”) in order to increase outflow and reduce eye pressure. The laser is performed by a laser mounted slit lamp and a mirrored lens that is placed on the eye. Glaucoma can be treated by lowering eye pressure with prescription eye drops, SLT laser or intraocular surgery performed by an ophthalmologist. Optometrists already have the authority to prescribe eye drops to treat glaucoma. Historically, eye drops were considered first line treatment for glaucoma, but recent studies (LiGHT trial below) suggest SLT laser is more effective as first line therapy and is repeatable. SLT laser surgery is effective for five to six years on average. The anatomical site for SLT laser surgery is located in the eye’s “angle” and requires visualization of the target tissue, the trabecular meshwork. To view this structure, clinicians use a special mirrored lens called a gonioscope, and the procedure itself is known as *gonioscopy*. Mastering gonioscopy can be challenging due to the narrow viewing angle, variations in ocular anatomy, and the need for patient cooperation.

A recent optometry journal article highlights these difficulties: *“Gonioscopy is an important ocular health assessment... Yet, many doctors in workshops we lead seldom perform gonioscopy. Why? Likely because they never really became confident in performing it and have now avoided it for so long that they have lost this clinical skill.”*

Gonioscopy is typically mastered during ophthalmology residency and is an essential technique used for diagnostic evaluations in the clinic, during SLT laser surgery, and in the operating room for *Microinvasive Glaucoma Surgery (MIGS)*—a rapidly growing area in glaucoma management.

Complications for SLT laser surgery can include elevated eye pressure, inflammation, corneal abrasions, retinal swelling or burns. If performed on certain types of secondary glaucoma (which are diagnosed by performing gonioscopy), SLT laser surgery can worsen the condition.

Depending on patient and surgeon preference, SLT can be performed in both eyes on the same day, and it is never needed on an emergency basis. And, as stated previously, effects can last more than 6 years. It is not unreasonable to ask a patient to see an ophthalmologist for this surgery.

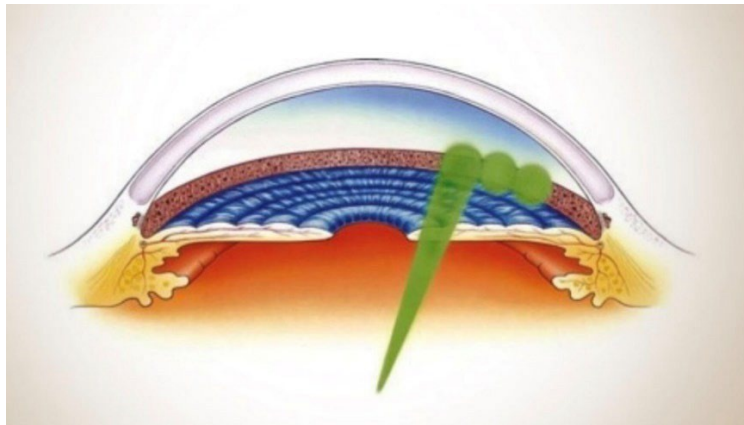
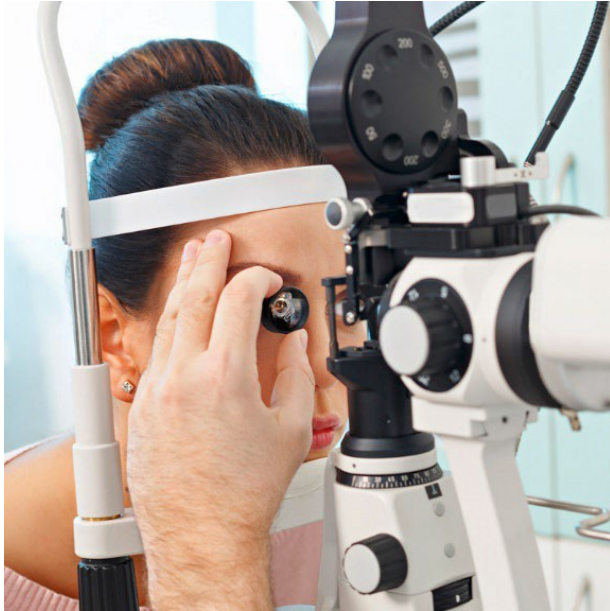

Image of angle drainage location and site of laser application

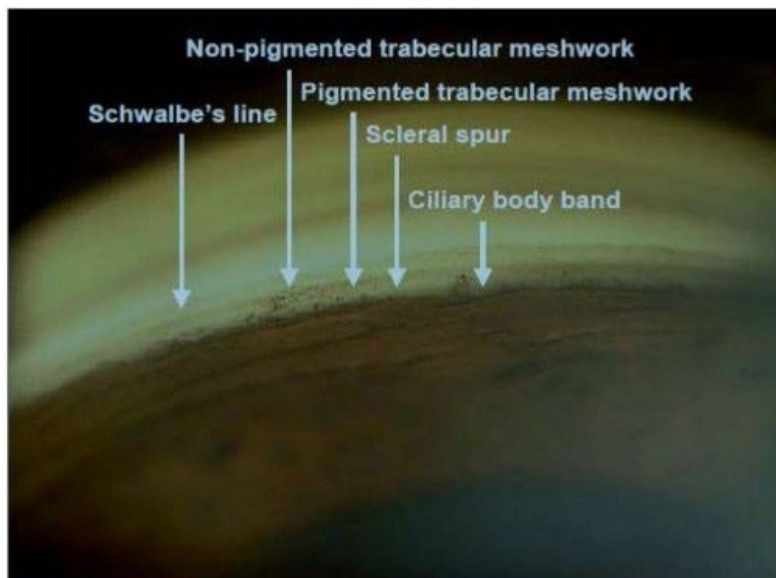
[Photo from: <https://www.wollongongeyedoctor.com.au/slt-gentle-laser-glaucoma-treatment>]

Gonioscopy exam:



[Photo from <https://my.clevelandclinic.org/-/scassets/images/org/health/articles/gonioscopy>]

GONIOSCOPIC VIEW OF ANGLE STRUCTURE



[Photo from <https://image.slidesharecdn.com/gonioscopy-140509084817-phpapp02/95/gonioscopy-47-638.jpg?cb=1399625384>]

At times, the view is challenging making differentiating angle structures difficult:

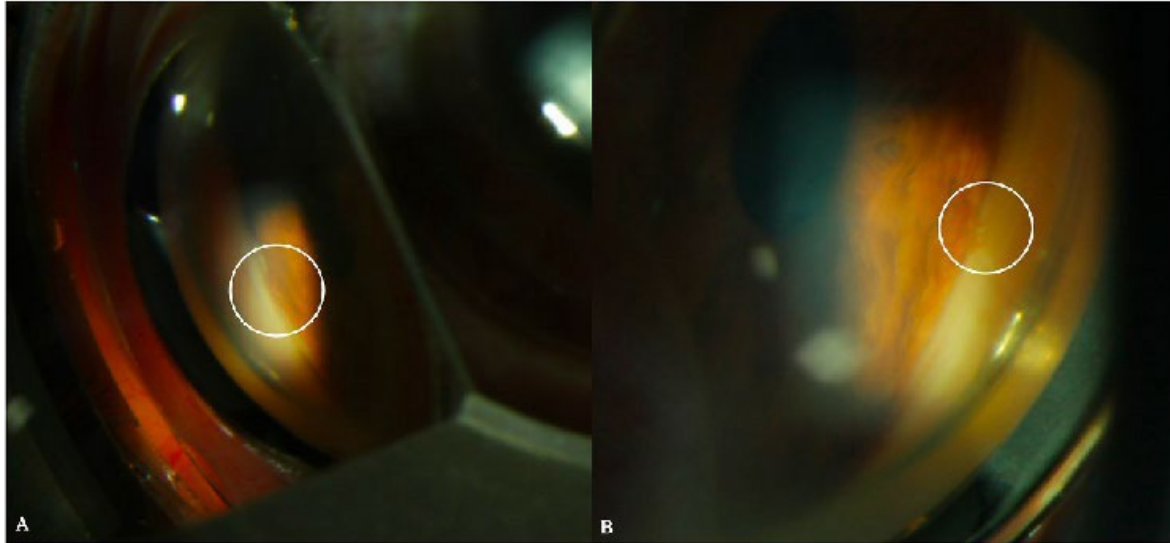


Photo from:

<https://www.researchgate.net/publication/369031984/figure/fig1/AS:11431281124854003@1678121546893/Slit-lamp-gonioscopy-photograph-of-the-right-eye-shows-A-peripheral-anterior-synechiae.png>

References:

<https://www.aao.org/eyenet/article/zap-light-and-salt>

<https://www.reviewofoptometry.com/article/gonioscopy-a-simple-tool-too-often-forgotten>

[https://eyewiki.org/Microinvasive_Glaucoma_Surgery_\(MIGS\)](https://eyewiki.org/Microinvasive_Glaucoma_Surgery_(MIGS))

Because laser eye surgery is so delicate and precise, ophthalmologists are trained under direct, one-on-one supervision to ensure they can perform it safely on live patients. Practicing on plastic model eyes is not an adequate substitute for this hands-on experience and does not equip optometrists to perform these surgeries safely.

Eyelid surgery. CPT: 11310-11313 Eyelid skin tag removal. CPT: 11200

Chalazion removal. CPT: 67800 / Kenalog injection. CPT: 96372 or 1190X

In office eyelid surgeries proposed involve removing benign skin growths, removing styes/chalazion or injecting triamcinolone (a corticosteroid) to speed resolution. The eyelid is a very delicate, thin-skinned structure. Just under the skin is a highly vascularized muscle with a rich network of blood vessels that are prone to bleeding. Just below the eyelid lies the eyeball. Eyelid surgeries require anesthetic that is injected under the skin surface with a needle. **Most family physicians, general surgeons, and often**

dermatologists refer their patients to ophthalmologists for eyelid surgeries due to the complex anatomical location.

Preaponeuroticfat

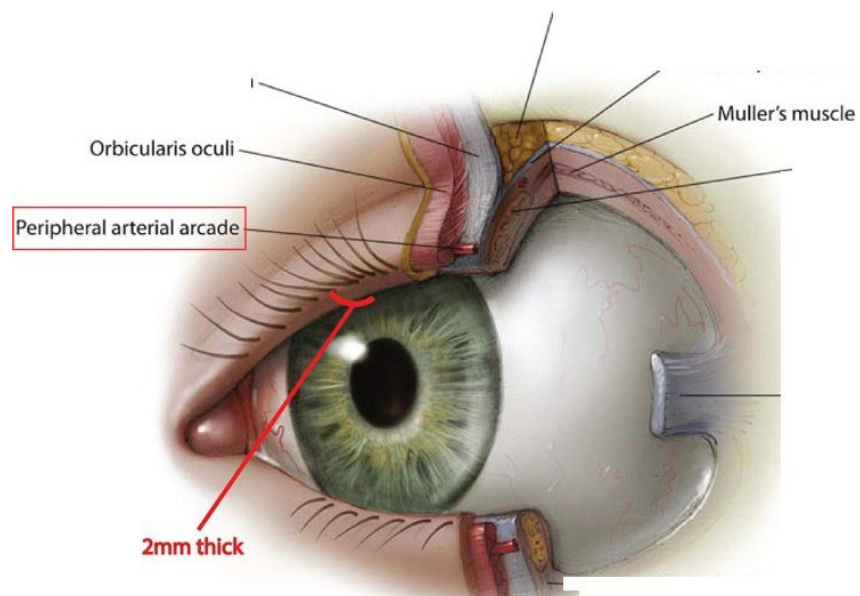
Orbital septum

Levator aponeurosis

Tarsus

Lateral palpebra ligament

---capsulopalpebral fascia



<https://Www.semanticscholar.org/paper/A.esthetic+i'yelid-reconstruction-Stein-Antonyflyn/2oa6calad6dc837f833S6t34ef0d436859f0059b/figure/12>

Figure 1: Eyelid anatomy

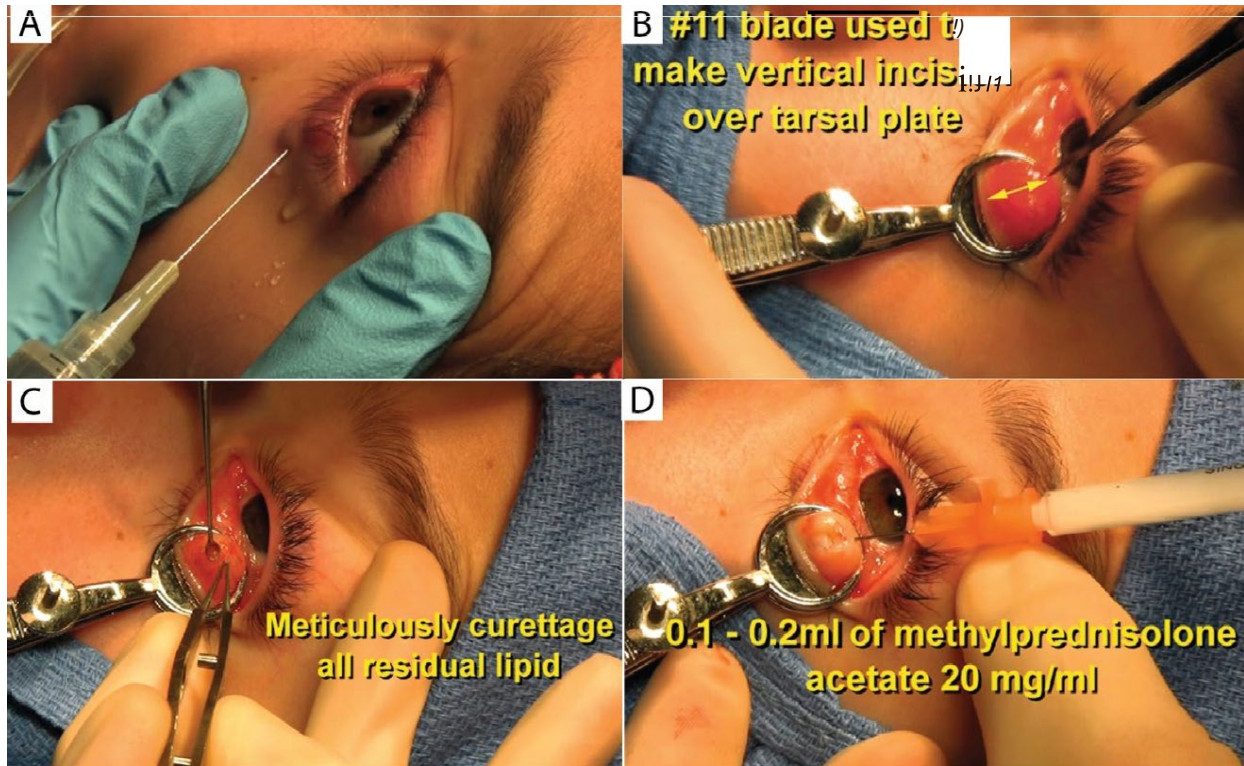


Figure 2: Eyelid surgery involves injections and cutting extremely close to the eye.

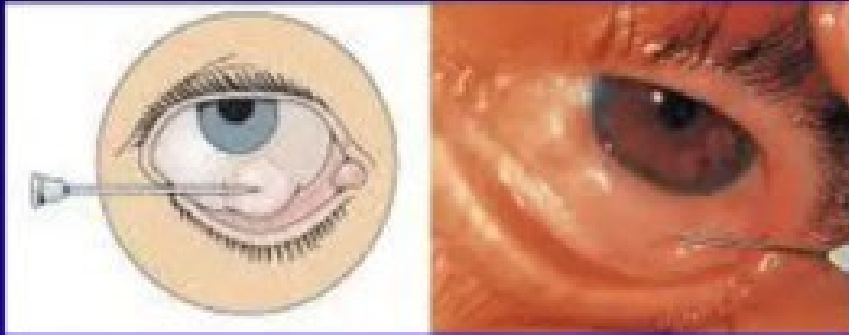
Chalazion removal from injection of anesthetic (A), incision (B), removal of material (C), and corticosteroid injection (D).

Complications of eyelid surgeries can include bleeding, disfiguring scarring, infection and eyeball perforation leading to further surgical interventions or even blindness. Injection of steroids into chalazia involves a needle which can pierce the eye or, rarely, cause a vascular occlusion leading to vision loss. LD 1803 cites authority to remove “**benign** skin lesions of the eyelid” (sec. 2 I.), however, many eyelid lesions cannot be identified as cancerous or noncancerous without pathology which requires a biopsy, special transport of the tissue, and coordination with a pathologist (usually at a hospital). Awareness of a patient’s medications and allergies along with the ability to manage blood thinners is mandatory. Patients can also experience vasovagal responses to surgery, resulting in dangerously low heart rate or blood pressure, with a loss of consciousness, seizures, falls and even heart attack, particularly in older, at-risk patients.

The vast majority of chalazia resolve without surgical intervention.

Subconjunctival Injections. CPT: 68200

Subconjunctival injection (Around the eye)



[Photo from [https://research: Better delivery of drugs and devices for Glaucoma](https://research.betterdeliveryofdrugsanddevicesforglaucoma.com)]

Subconjunctival injection is a type of ocular drug administration to the periocular region of the eye. Medicine is deposited via needle under the conjunctiva and adjacent to the wall of the eye (sclera) to prolong or increase drug absorption. The needle used must be precisely placed adjacent to the eye without piercing the eye wall. Risks include bleeding, infection, wrong placement of medication, perforation of the eye wall. If the medication is a steroid depot, such as kenalog (very common), sustained eye pressure elevation can occur leading to glaucoma and potential blindness.