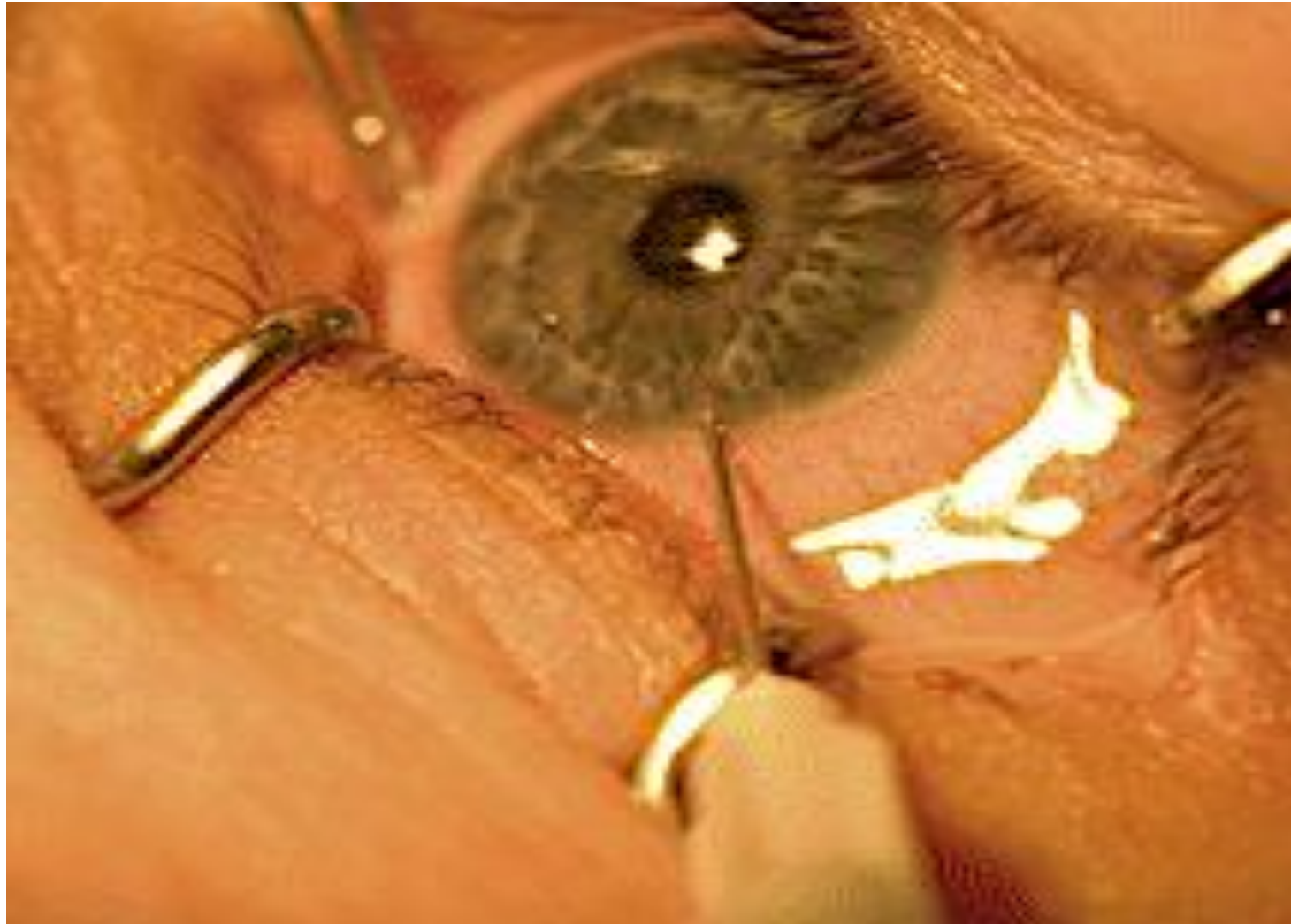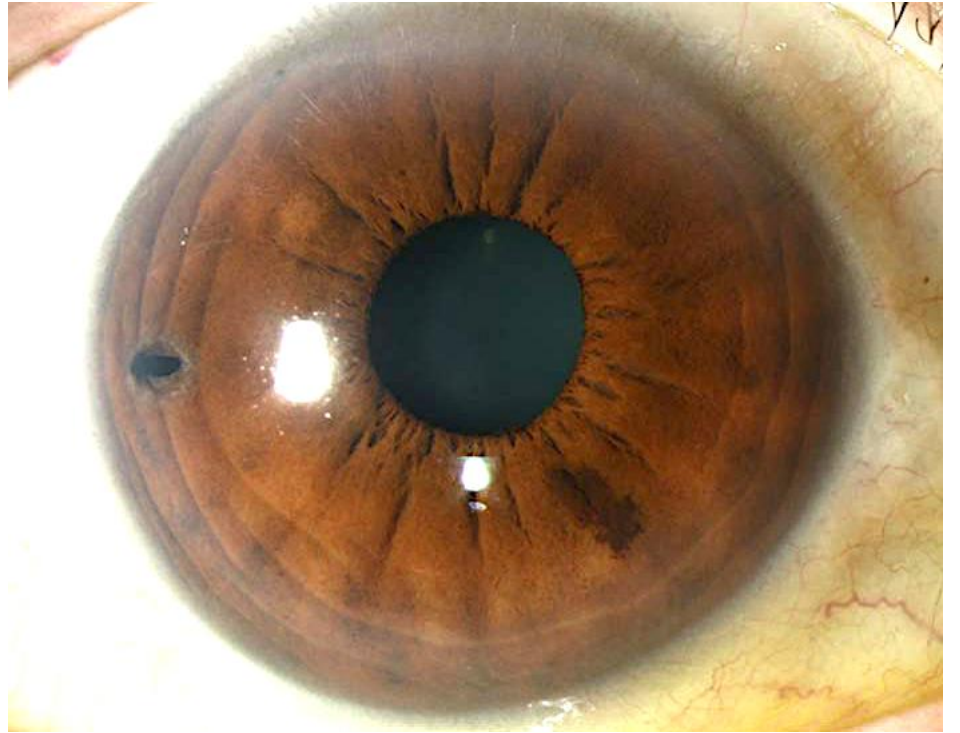
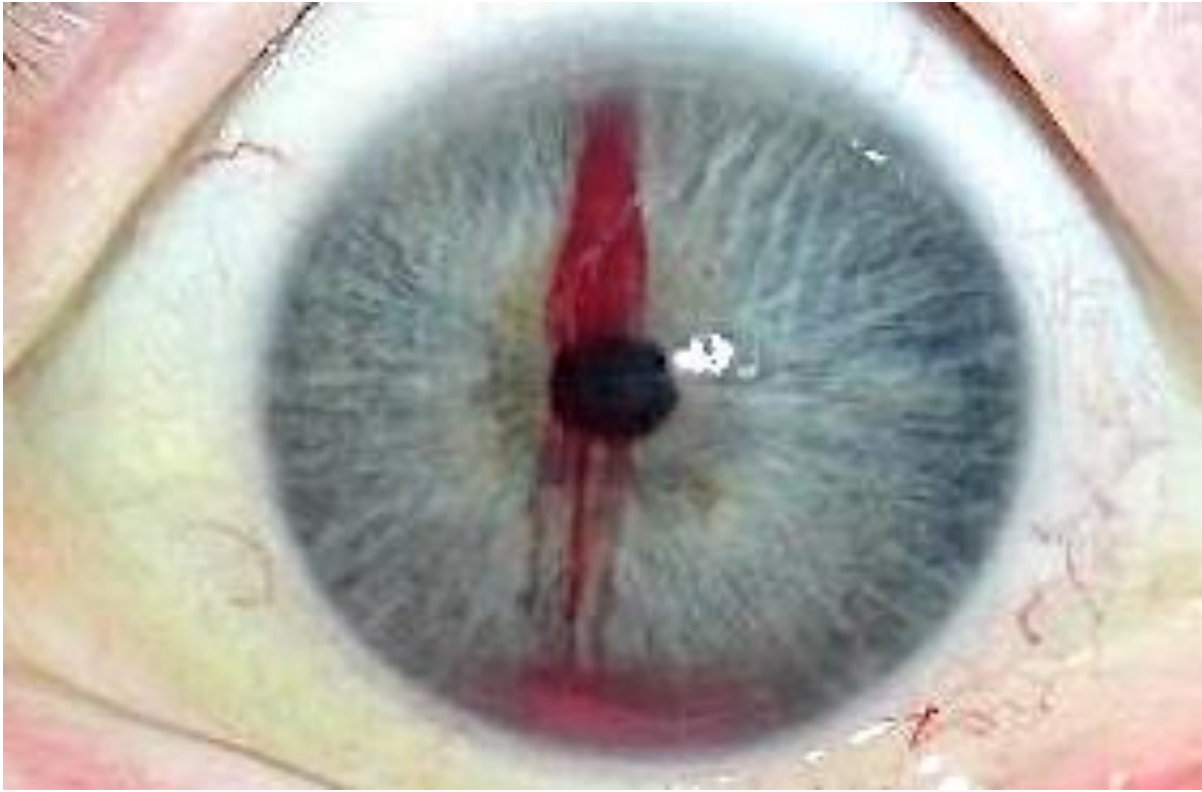


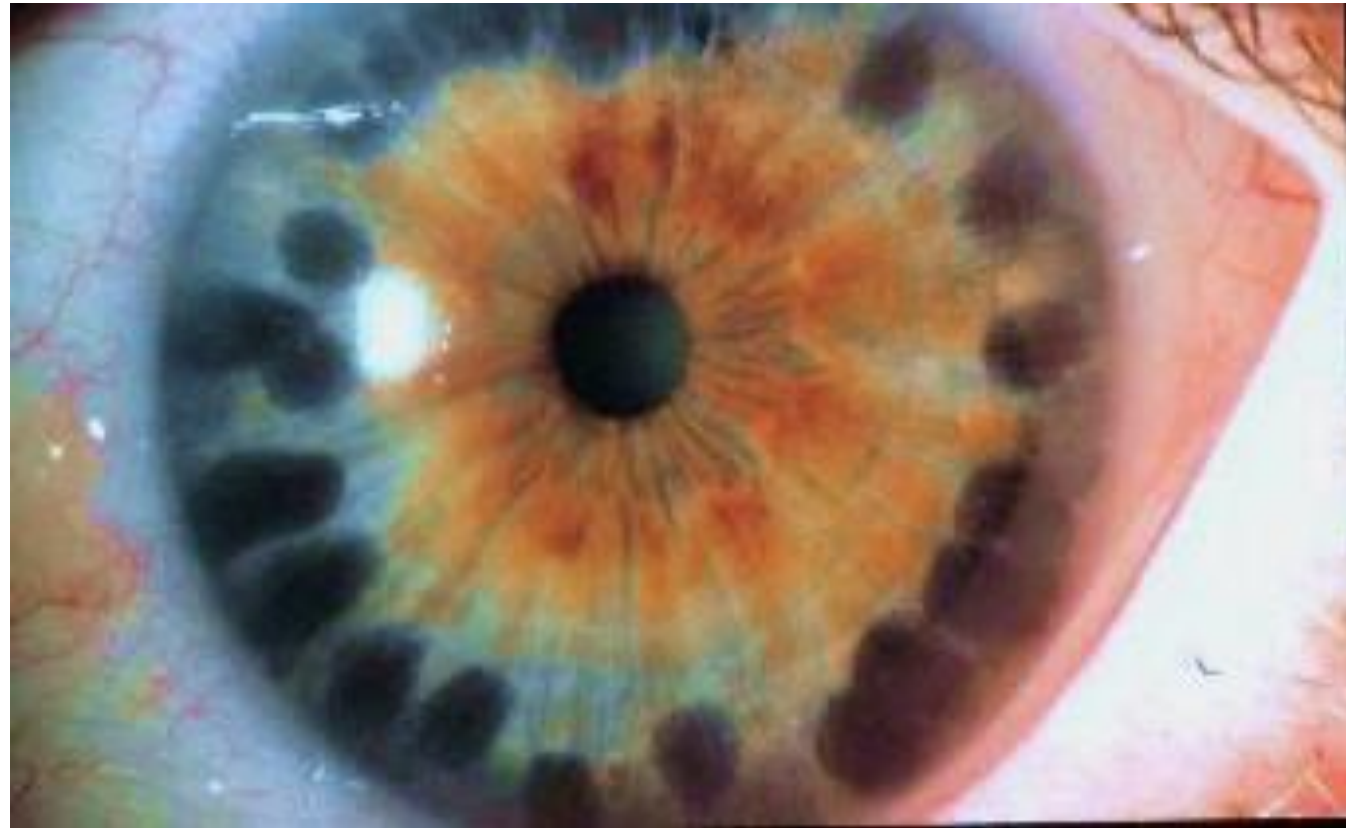Anterior “paracentesis in an emergency setting” page 8



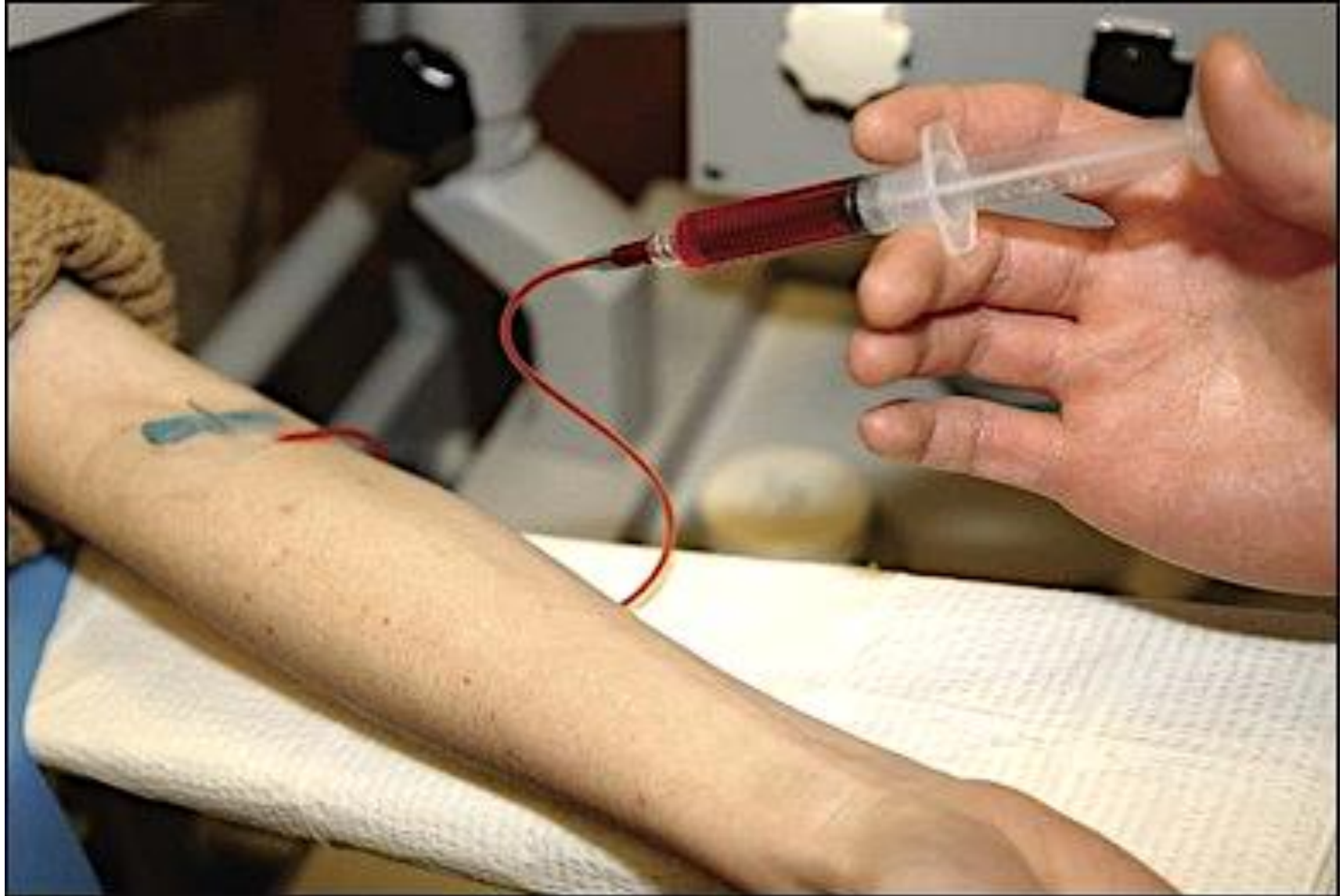Laser iridotomy



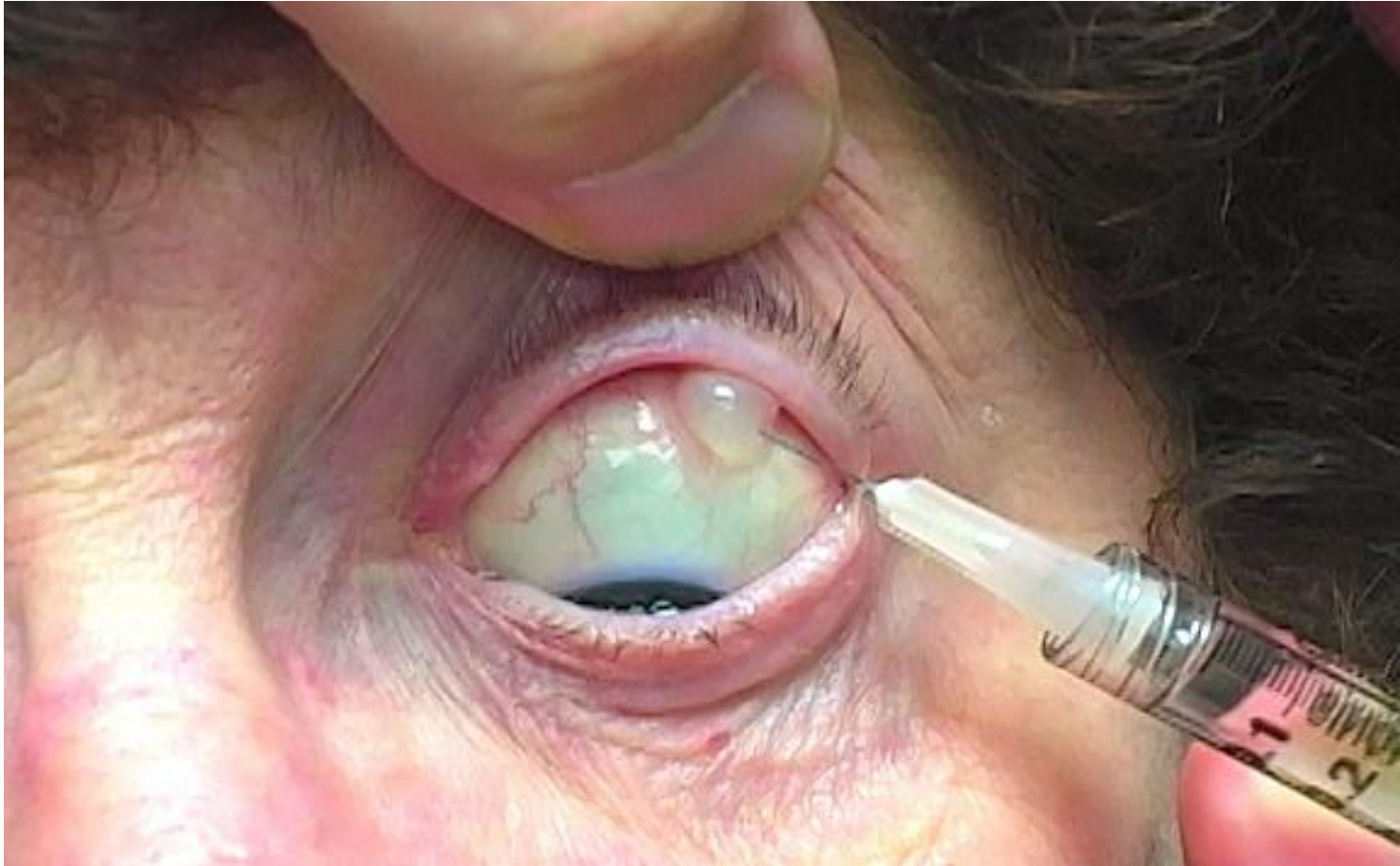Laser iridoplasty



Injection of fluorescein dye



Subconjunctival injection



Chalazion excision

