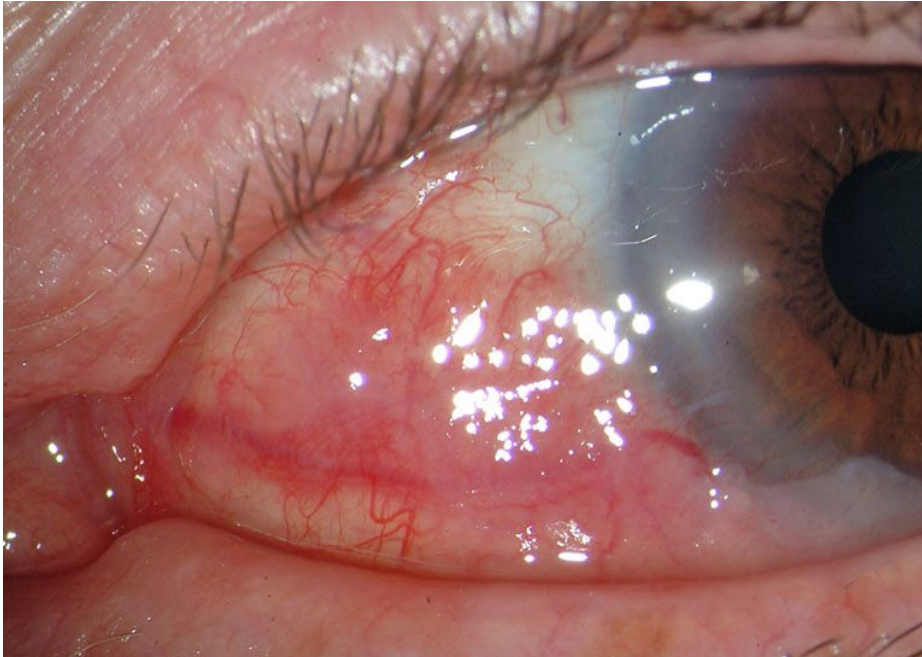
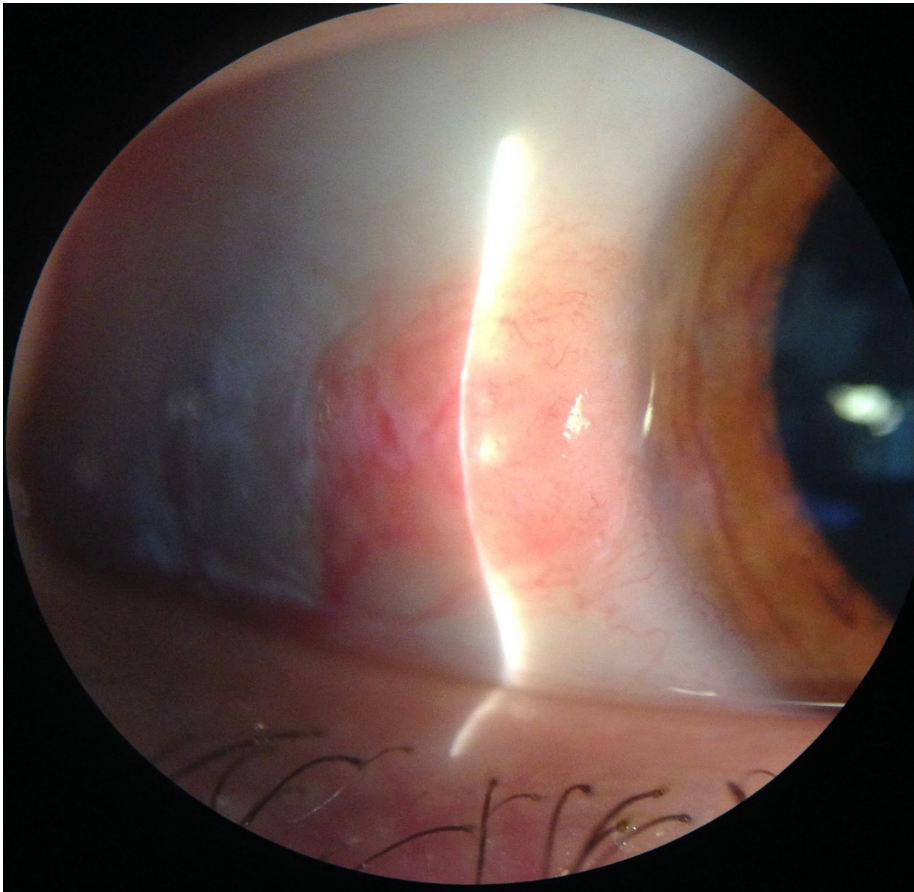


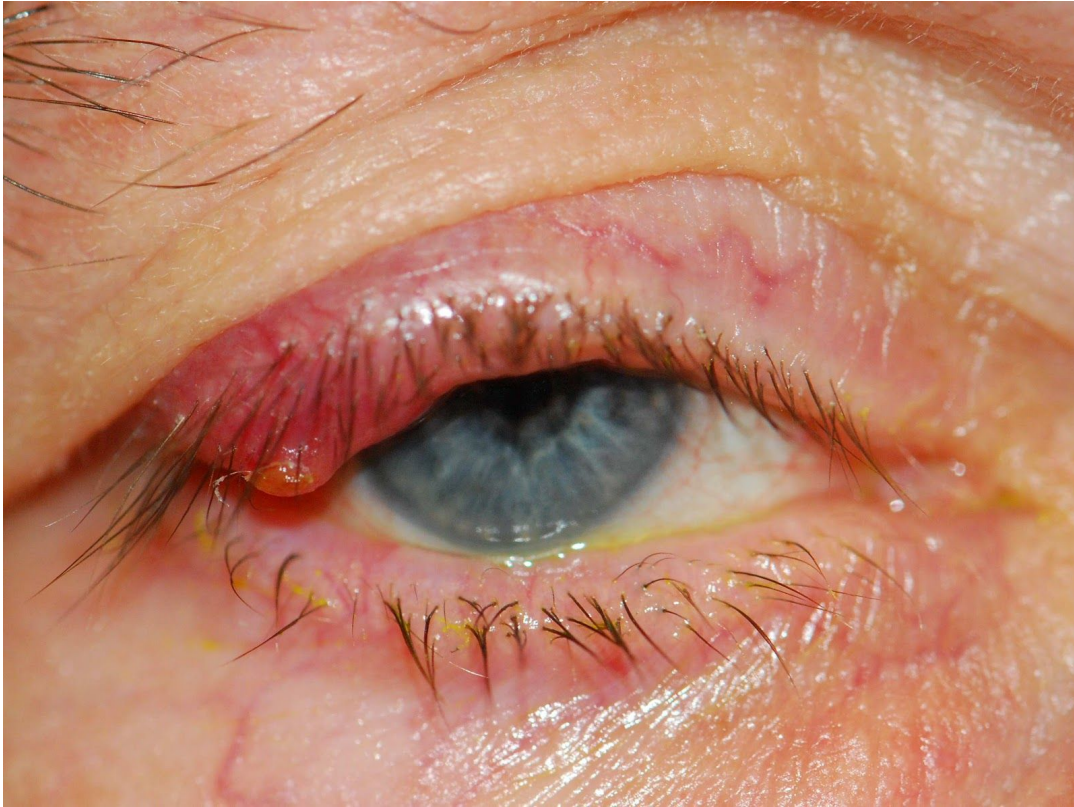Ocular Surface Squamous Neoplasia- malignant



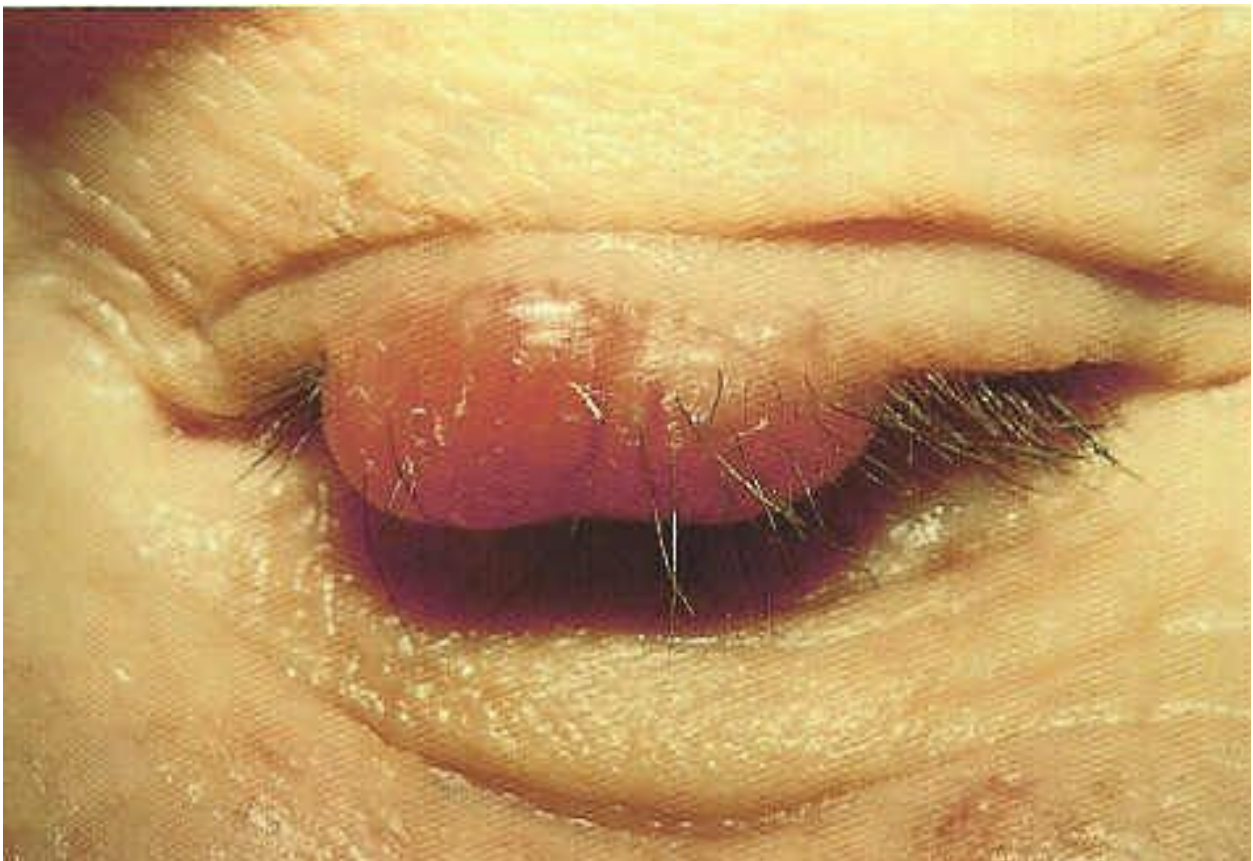Inflamed Juvenile Compound Nevus- benign



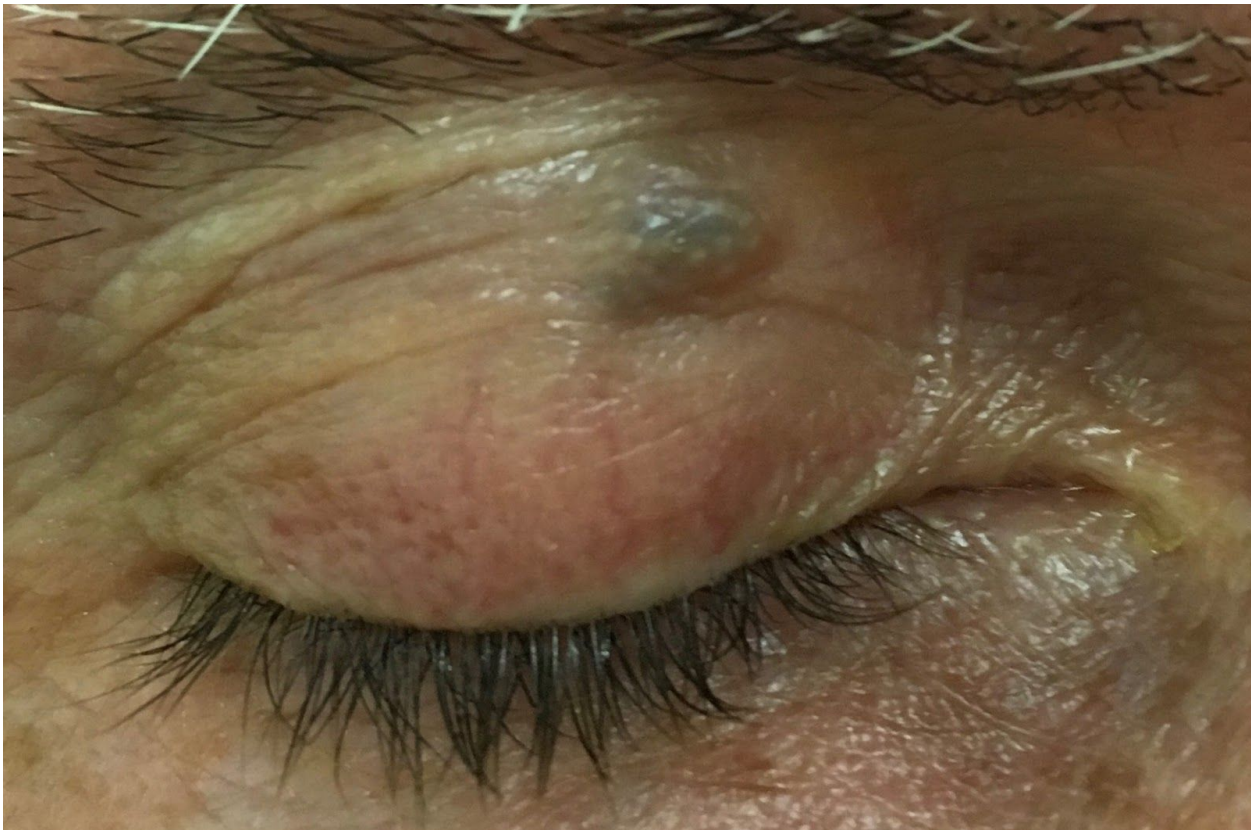
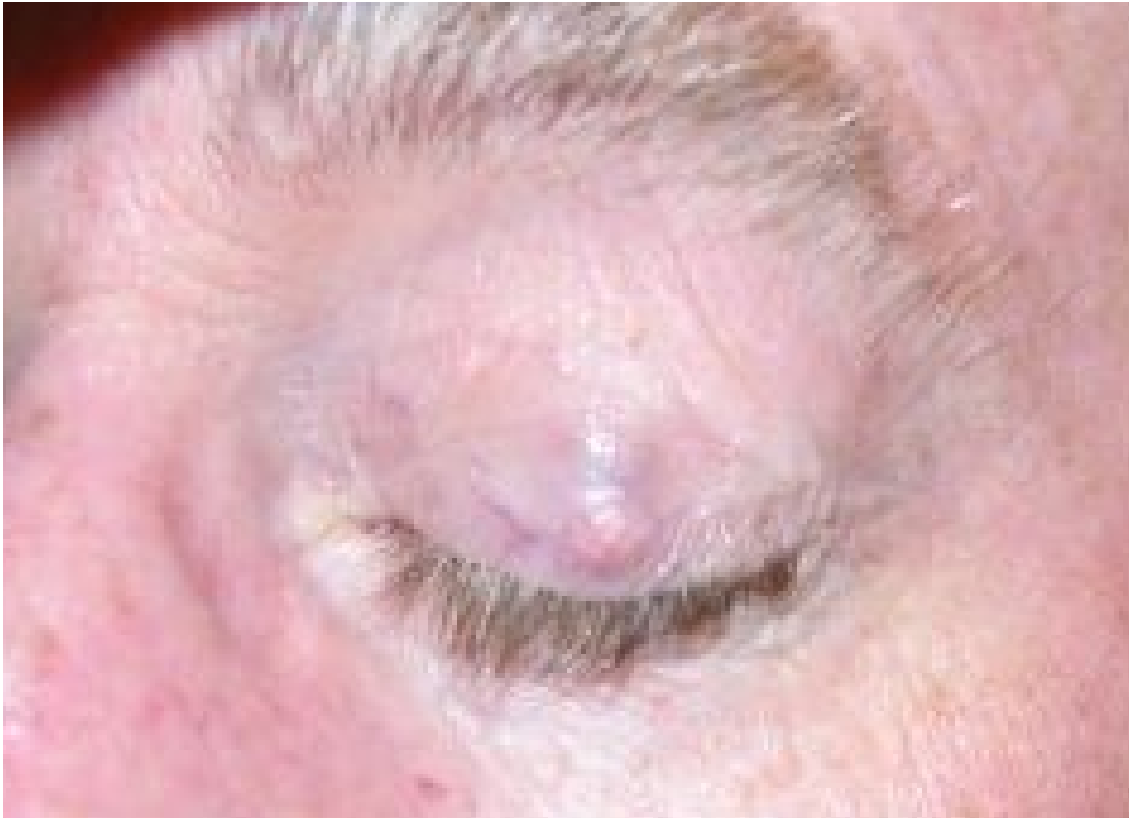Chalazion- benign



Lymphoma- malignant

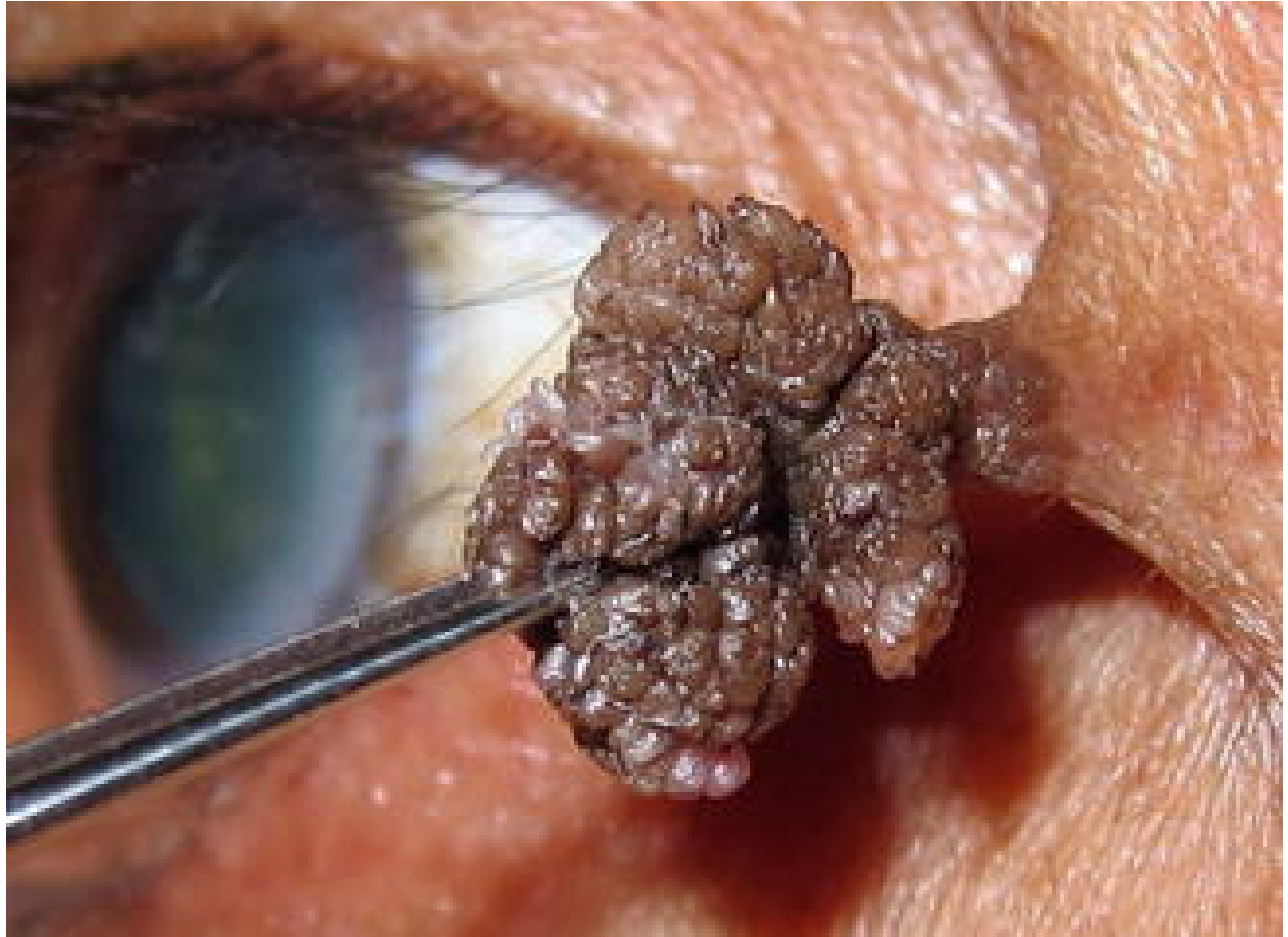

Sebaceous Cell Carcinoma- malignant



Intradermal nevus- benign

Pigmented Squamous Papilloma- benign



Melanoma- malignant

